



Sandwich Osteotomies to Treat Vertical Defects of the Alveolar Ridge

Claudio Ferreira Nóia, PhD,* Rafael Ortega-Lopes, PhD,† Leandro Eduardo Kluppel, PhD,‡ and Bruno Costa Martins de Sá, PhD§

Reabsorption of the alveolar bone is a common problem after dental extractions. This occurs because the role of the alveolar process is to provide sustenance for the teeth, and the loss of this function leads to gradual reabsorption.^{1–4} This reabsorption process culminates in defects related to bone height, bone thickness, or associated problems, which hinder the installation of dental implants, thereby creating the need for a bone graft.^{5–8}

It is known that the treatment of height defects remains a great challenge for surgeons today.^{9–12} According to the literature, the factors that have the greatest direct and negative effect on the results of this type of reconstruction include the high index of exposure and the difficulties associated with the nutrition of bone grafts (block or particles), when performed on the alveolar ridge in areas with this type of defect.^{11,13,14}

In recent years, sandwich osteotomy with the interposition of a bone graft has become more common when

Purpose: To evaluate the vertical bone gain after osteotomy sandwich.

Materials and Methods: Fourteen patients (mean age, 41 years) underwent 17 procedures of osteotomy sandwich. Of these 17 procedures, 15 involved reconstructive surgery and 2 involved the repositioning of implants. The patients were submitted to computed tomography before the surgical procedure and 4 months after the completion of the graft, with measurements taken to assess the vertical gain that had been achieved.

Results: The results confirmed a satisfactory vertical gain in all cases (mean, 5.12 mm). The use of autogenous graft or biomaterial

particles (in isolation) between the osteotomized segments proved to be viable. Three patients reported postoperative paresthesia, which healed spontaneously after 3 months. One patient exhibited dehiscence due to not following the postoperative recommendations. Forty implants were installed in the grafted regions, and 2 implants were repositioned.

Conclusion: The technique of sandwich osteotomy was found to be effective for height gain, and different materials can be used between the osteotomized segments. (*Implant Dent* 2017;26:101–105)

Key Words: alveolar bone loss, interpositional bone graft, dental implants

treating these conditions, due to the low rate of exposure, the lack of complications, the ease of nutrition for the graft, and the high success rates.^{10–14} With this technique, it is possible to readjust height defects of between 4 and 8 mm and to reposition poorly installed implants, thereby improving long-term function, esthetics, and stability.^{10,13–16}

Given the above, the aim of the present study was to report our experience with sandwich osteotomy in 17 consecutive cases, in which this technique was used to treat bone height defects or to reposition implants.

MATERIALS AND METHODS

The sample contained 14 patients (8 women and 6 men), with a mean age

of 41 years (ranging between 30 and 54 years). All of the participants had sought the services of the Oral and Maxillofacial Surgery Department and exhibited either vertical atrophy of the alveolar ridge or a badly positioned implant (Table 1). All of the patients were treated using sandwich osteotomy. The surgical procedures were performed by 2 surgeons following standardized technical procedures.

The patients included in the present study were assessed using cone beam computed tomography and exhibited either a bone height defect that required a vertical gain of between 4 and 8 mm (technical indication) or a badly positioned implant, which needed to be repositioned in the

*Professor, Dentistry Department, University of Araras Dental School, Araras, Brazil.

†Professor, Dentistry Department, APCD Piracicaba Dental School, Piracicaba, Brazil.

‡Professor, Dentistry Department, Parana Federal University Dental School, Curitiba, Brazil.

§Professor, Dentistry Department, College Ciodonto Dental School, Porto Velho, Brazil.

Reprint requests and correspondence to: Claudio Ferreira Nóia, PhD, Dentistry Department, University of Araras (UNARARAS), Avenida Doutor Maximiliano Baruto, 500, Jardim Universitário, Araras 13607-339, Brazil, Phone/Fax: (55)19-98323 9526, E-mail: claudioferreira2004@yahoo.com.br

ISSN 1056-6163/17/02601-101

Implant Dentistry

Volume 26 • Number 1

Copyright © 2017 Wolters Kluwer Health, Inc. All rights reserved.

DOI: 10.1097/ID.0000000000000522

Table 1. Characteristics of the Sample

Patient No.	Gender	Age, y	VBD or BPI	Region of VBD or the BPI	Absent Teeth
1	M	45	VBD	Mandible posterior	34, 35 e 36
2	M	42	VBD	Mandible posterior	44, 45, 46
3	F	50	VBD	Mandible posterior	45, 46
4	F	38	VBD	Mandible posterior	35, 36, 37
5	F	44	VBD	Mandible posterior	44, 45, 46
6	M	40	VBD	Maxilla posterior	14, 15, 16
7	F	30	VBD	Maxilla anterior	11, 21
8	F	35	VBD	Maxilla anterior	11, 12, 21, 22
9	M	26	BPI	Maxilla anterior	21
10	M	32	BPI	Maxilla anterior	11
11	M	45	VBD	Mandible anterior	31, 32, 41, 42
12	F	54	VBD	Mandible posterior (bilateral)	34, 35, 36, 44, 45, 46
13	F	52	VBD	Mandible posterior (bilateral)	35, 36, 37, 45, 46, 47
14	F	46	VBD	Mandible posterior (bilateral)	34, 35, 36, 44, 45, 46

Variables are presented as gender, age, vertical bone defect or badly-positioned implant, the region of bone defect or the implant region, and missing teeth.

BPI indicates badly positioned implant; M, male; F, female; VBD, vertical bone defect.

occlusal direction. None of the patients reported any clinically relevant medical history that could have interfered with the results.

Surgical Procedure

Sandwich osteotomy began with the performance of an anesthetic block, using articaine solution (4%) and a 1:100,000 vasoconstrictor (Dfl, Rio de Janeiro, Brazil), followed by a linear incision located 3 mm beyond the mucogingival junction. Subsequently, mucoperiosteal displacement was conducted, and vertical and horizontal osteotomies were created using a micro sagittal saw (Dentscler, Ribeirão Preto, Brazil). The finishing of the osteotomies, as well as the mobilization of the bone segment, were conducted using chisels (Quinelato, Rio Claro, Brazil), taking care not to lacerate the palatal or lingual mucosa (Figs. 1 and 2).

Subsequently, a bone block was removed from the mandibular ramus or menton (or biomaterial particles were used in isolation [Lumina-Bone Critéria, São Carlos, Brazil]) and was interposed in the space created by the mobilization of the bone segment. The ensemble was fixed with a plate and 1.5-mm screws (Engimplan, Rio Claro, Brazil) or with screws in isolation

(Engimplan) or without any type of fixation (Fig. 3).

A layer of biomaterial particles and a resorbable collagen membrane were placed on the graft area in all cases involving the use of autogenous bone (Lumina-Bone and Lumina-Coat; Critéria). When biomaterial particles were used in isolation, only the collagen membrane was placed on the area in question (Fig. 4). The procedure was finished with continuous suture and absorbable thread (Catgut 3-0; Point Suture, Fortaleza, Brazil).

After a period of 4 months, all of the patients were submitted to another session of computed tomography (Fig. 5), and candidates for the installation of dental implants were reassessed for the procedure. After careful mucoperiosteal displacement, the fixation system was removed, and the dental implants were installed, according to the relevant surgical guide and reverse planning (Fig. 6).

Assessment Method

Cone beam computed tomography was used to assess the vertical gain achieved. This procedure was conducted immediately before the surgical procedure and in the 4-month postoperative period.

The tomography was always conducted using the same methods and x-ray apparatus. Bone height was measured by the same examiner, according to the following parameters (Fig. 7): (1) posterior region of the mandible: distance between the upper cortical bone of the inferior alveolar nerve and the crest of the alveolar ridge, 15 mm behind the last tooth; (2) anterior region of the mandible: Distance between the mandibular base and the crest of the alveolar ridge, considering the midline; (3) posterior region of the maxilla: distance between the floor of the maxillary sinus and the crest of the alveolar ridge, 15 mm behind the last tooth; (4) anterior region of the maxilla: distance between the floor of the nasal cavity and the crest of the alveolar ridge, considering the midline; (5) in the cases involving the repositioning of implants, the distance between the floor of the nasal cavity and the cover screw was analyzed.

RESULTS

Seventeen sandwich osteotomy procedures were conducted on the 14 patients included in the present study (3 patients were submitted to bilateral procedures in the posterior region of the mandible).

As can be seen in Table 2, a satisfactory bone gain was achieved in all the procedures. The mean vertical gain was 5.12 mm (ranging from 2 to 7.88 mm). In total, 40 implants were installed on the graft area and 2 implants were repositioned.

In 10 of the procedures, autogenous bone was the material of choice for the interposition between osteotomized segments. Biomaterial in isolation was used in 7 of the procedures. From a clinical point of view, at the time of implant installation, the cases involving the use of autogenous bone were in a more advanced stage of incorporation. Nevertheless, both of the materials in question enabled the installation of the implants as planned.

In the 7-day postoperative period, 3 patients who had undergone surgery in the posterior region of the mandible reported a loss of sensitivity (the distance between the upper cortical bone




Fig. 1. Panoramic image of the cone beam computed tomography showing the atrophy in the posterior region of the mandible, with a consequent indication for sandwich osteotomy.

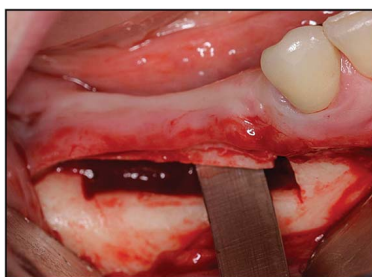


Fig. 2. After the mucoperiosteal displacement, vertical and horizontal osteotomies were carried out to enable careful mobilization of the osteotomized segment.

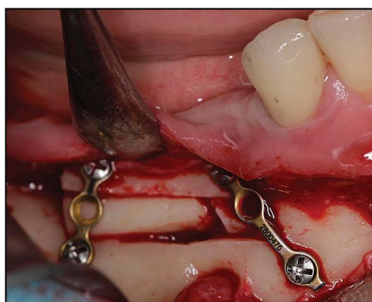

Fig. 3. Bone segment fixed with plates and titanium screws. In this case, a bone block, removed from the mandibular ramus, was interposed.

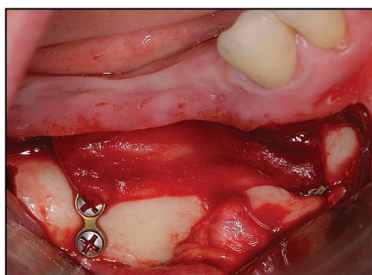


Fig. 4. In the cases involving the interposition of autogenous bone between the osteotomized segments, together with heterogeneous biomaterial particles to fill the gaps, a collagen membrane was used to inhibit tissue interposition.

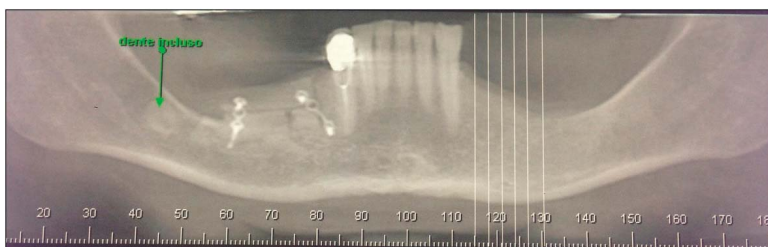


Fig. 5. Panoramic image of the cone beam computed tomography showing the vertical bone gain obtained through sandwich osteotomy.

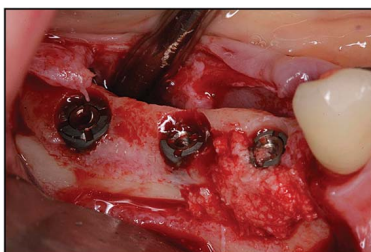


Fig. 6. Implants installed in the graft region (Ankylos; Destsply-Friadent, Mannheim, Germany).

of the inferior alveolar nerve and the crest of the alveolar ridge was less than 6 mm in these cases). Ninety days after the surgery, these patients reported that their sensitivity levels had spontaneously returned to normal.

Another complication that occurred was associated with suture dehiscence. One patient returned on the third day for this reason and admitted that he or she had not followed the postoperative instructions (smoking immediately after the surgical procedure and not maintaining adequate oral hygiene). This individual was submitted to debridement in the region and a new suture session. They were also warned of the importance of not smoking and maintaining adequate oral hygiene habits. In the case of this

individual, the vertical gain achieved was only 2 mm (Table 3).

DISCUSSION

The aim of modern implantology is to restore the patient’s masticatory function, comfort, esthetics, and phonetics, regardless of the existence of atrophy, disease, or injuries of the stomatognathic system.^{10,13–16}

Sandwich osteotomy was first described by Schettler and Holtermann,⁹ in an attempt to increase the retention of complete lower dentures. Over time, with the performance of new studies, the advances in technology, and the satisfactory results linked to this technique, sandwich osteotomy began to be used in cases involving vertical defects and implant installation.^{10–12} Bormann et al,³ demonstrated that this technique even favors gains in the thickness of the alveolar ridge, due to the inclination that occurs in the osteotomized segment.

Studies have shown that this technique is relatively easy to perform and

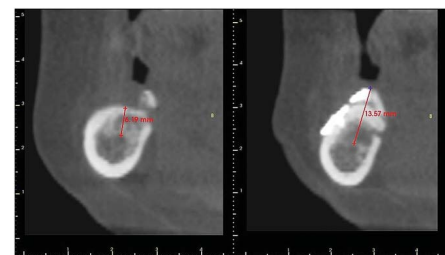


Fig. 7. Measurement taken during the cone beam computed tomography immediately before the surgical procedure and in the 4-month postoperative period. A vertical gain of 7.38 mm was recorded in the case involving the posterior region of the mandible.

Table 2. Results Found When Comparing the Bone Height in the Preoperative Tomography Session With the Bone Height in the 4-Month Postoperative Tomography Session

Patient No.	Bone Height—Initial (mm)	Bone Height—End (mm)	Vertical Bone Gain (mm)	No. Implants
1	6.40	10.58	4.18	3
2	5.88	10.93	5.05	3
3	6.5	11	4.5	2
4	7.5	12	4.5	3
5	6.32	12	5.68	3
6	16.53	22.79	6.26	3
7	14	20	6	2
8	12.68	17.77	5.09	2
9	20	25.64	5.64	Repositioning the implant
10	18.42	26.30	7.88	Repositioning the implant
11	23.55	25.55	2	2
12 Right side	6.19	13.57	7.38	3
12 Left side	7.22	11.35	4.13	3
13 Right side	8	12	4	3
13 Left side	5.55	10	4.45	3
14 Right side	5.48	10.30	4.82	3
14 Left side	6.96	12.50	5.54	3

Note the vertical gain obtained in all cases and the quantity of dental implants placed in grafted regions.

provides clinically satisfactory results. It is also a highly predictable method, due to the fact that the graft remains in contact with a 4-walled defect, which is highly favorable for its nutrition and promotes a considerably lower degree of resorption.^{2-4,6}

The mean vertical gain obtained in the present study was 5.12 mm, which is similar to that found in other studies published in the literature.^{2-4,6,11-14} This confirms the versatility, predictability, and reproducibility of the technique in different parts of the world.

Based on our experiences with sandwich osteotomy, gains of more than 5 mm are hindered by the rigidity of the palatal mucosa (when operating on the maxilla) and by the lingual tendency of the osteotomized ensemble (when operating on the mandible).

The use of autogenous bone between osteotomized segments is widespread in the literature.^{2-4,11-15} However, the use of biomaterial in isolation is not so common. In the present study, the incorporation process was slower in all cases that involved the isolated use of biomaterial, when compared with the autogenous bone cases. Nevertheless, both types of material enabled the successful installation of the implants as planned.

It is notable that only 3 patients reported postoperative paresthesia, and these patients exhibited a distance of less than 6 mm between the upper cortical bone of the inferior alveolar nerve and the crest of the alveolar ridge in the preoperative tomography. The authors of the present study were unable to find similar results in the literature, which suggests that this research is unique and illustrative.

CONCLUSION

Sandwich osteotomy provides a satisfactory and predictable bone gain. The use of autogenous bone or biomaterial between the osteotomized segments was both shown to be viable. Patients who exhibit less than 6 mm of remaining bone in the posterior region of the mandible represent a greater risk of paresthesia.

DISCLOSURE

The authors claim to have no financial interest, either directly or indirectly, in the products or information listed in the article.

APPROVAL

This study was approved by the Ethics Committee in Research of Piracicaba Dental School, with the protocol 040.

REFERENCES

1. Choi BH, Lee SHR, Huh JY, et al. Use of the sandwich osteotomy plus an

Table 3. Results Found When Comparing the Type of Graft, the Type of Fixation, and Any Subsequent Complications

Patient No.	Type of Graft	Osteosynthesis	Complications
1	Autogenous	Plate and screws	No
2	Autogenous	Plate and screws	Yes (paresthesia)
3	Biomaterial	Plate and screws	No
4	Biomaterial	Plate and screws	No
5	Autogenous	Plate and screws	No
6	Autogenous	Plate and screws	No
7	Biomaterial	Plate and screws	No
8	Autogenous	Plate and screws	No
9	Biomaterial	Only screw	No
10	Autogenous	No	No
11	Autogenous	Plate and screws	Yes (dehiscence)
12 Right side	Autogenous	Plate and screws	No
12 Left side	Autogenous	Plate and screws	No
13 Right side	Biomaterial	Plate and screws	No
13 Left side	Autogenous	Plate and screws	Yes (Paresthesia)
14 Right side	Biomaterial	Plate and screws	Yes (Paresthesia)
14 Left side	Biomaterial	Plate and screws	No

In most cases, it was performed with autogenous graft and fixed with plate and screws. Only 4 patients had postoperative complications.

interpositional allograft for vertical augmentation of the alveolar ridge. *J Craniomaxillofac Surg.* 2004;32:51–54.

2. Jensen OT. Alveolar segmental “sandwich” osteotomies for posterior edentulous mandibular sites for dental implants. *J Oral Maxillofac Surg.* 2006;64:471–475.

3. Bormann KH, Suarez-Cunqueiro MM, von See C, et al. Sandwich osteotomy for vertical and transversal augmentation of the posterior mandible. *Int J Oral Maxillofac Surg.* 2010;39:554–560.

4. Hashemi HM, Javidi B. Comparison between interpositional bone grafting and osteogenic alveolar distraction in alveolar bone reconstruction. *J Oral Maxillofac Surg.* 2010;68:1853–1858.

5. Politi M, Robiony M. Localized alveolar sandwich osteotomy for vertical augmentation of the anterior maxilla. *J Oral Maxillofac Surg.* 1999;57:1380–1382.

6. Jensen OT, Kuhlke L, Bedard JF, et al. Alveolar segmental sandwich osteotomy for anterior maxillary vertical

augmentation prior to implant placement. *J Oral Maxillofac Surg.* 2006;64:290–296.

7. Kluppel LE, Nória CF, Mazzonetto R. *Reconstruções em implantodontia, protocolos clínicos para o sucesso e previsibilidade.* Mazzonetto R, ed. Nova Odessa, Brazil: Napoleão; 2008:250–280.

8. López-Cedrun JL. Implant rehabilitation of the edentulous posterior atrophic mandible: The sandwich osteotomy revisited. *Int J Oral Maxillofac Implants.* 2011;26:195–202.

9. Schettler D, Holtermann W. Clinical and experimental results of a sandwich-technique for mandibular alveolar ridge augmentation. *J Maxillofac Surg.* 1977;5:199–202.

10. Nória CF, Ortega-Lopes R, Mazzonetto R, et al. Segmental osteotomy with interpositional bone grafting in the posterior maxillary region. *Int J Oral Maxillofac Surg.* 2012;41:1563–1565.

11. Bormann KH, Suarez-Cunqueiro MM, von See C, et al. Forty sandwich osteotomies in atrophic mandibles: A retrospective study. *J Oral Maxillofac Surg.* 2011;69:1562–1570.

12. Laviv A, Jensen OT, Tarazi E, et al. Alveolar sandwich osteotomy in resorbed alveolar ridge for dental implants: A 4-year prospective study. *J Oral Maxillofac Surg.* 2014;72:292–303.

13. Bell RE. Palatal approach to the anterior maxillary sandwich osteotomy. *J Oral Maxillofac Surg.* 2013;71:1005–1009.

14. Triaca A, Bruscoa D, Asperio P, et al. New perspectives in the treatment of severe mandibular atrophy: “double sandwich” osteotomy. *Br J Oral Maxillofac Surg.* 2014;52:664–666.

15. Felice P, Barausse C, Pistilli R, et al. Guided “sandwich” technique: A novel surgical approach for safe osteotomies in the treatment of vertical bone defects in the posterior atrophic mandible: A case report. *Implant Dent.* 2014;23:738–744.

16. Feng Xuan F, Chun-Ui Lee CU, Son JS, et al. Vertical ridge augmentation using xenogenous bone blocks: A comparison between the flap and tunneling procedures. *J Oral Maxillofac Surg.* 2014;72:1660–1670.