

Aesthetic Rehabilitation with a Dental Implant in an Upper Central Incisor

Aline Ehlert¹, Cibelle Correia Cavalcante Lacerda², Nataly Clyce da Silva Baracho², Bruno Santana Freitas², Felipe Andres Ortiz Poblete², Sérgio Charifker Ribeiro Martin², Leandro Lécio de Lima Sousa² and Tiago Garcia Margute*¹

¹ Departamento de Implantodontia, Centro Universitário UNINGÁ, BRASIL.

² ICS Departamento de odontologia, FUNORTE, Centro Universitário Faculdades Norte de Minas Gerais, Brasil.

*Corresponding Author: Dr. Tiago Garcia Margute, Departamento de Implantodontia - Centro Universitário UNINGÁ, BRASIL.

Received: December 19, 2021 Published: December 27, 2021

Abstract:

Implant-supported prosthetic rehabilitation in the maxilla of only one central incisor, is a great challenge for the dentist. It is a true work of art when you get the perfect reproduction, exact of a central incisor because of the difficulty of reproducing, with nuances of color, degrade, transparencies, curvatures and textures. Harmony is the relation of several different parts to each other that forms a whole, and should not only be present in the face, but also in the smile, because a perfect smile, harmonic, white in many cases, is very demanded Society. The use of osseointegrative implants has contributed a lot to a better aesthetic resolution of these cases, since they provide the replacement of an individualized crown, similar to a natural tooth, in which it is possible to manipulate the bone and gingival tissue in search of these results. Thus, the objective of this work is to report the aesthetic rehabilitation of a central incisor lost in the maxilla, where it was necessary to associate procedures such as bone grafting together with the installation of osseointegrable implant, manipulation of the peri-implant tissue and the choice of aesthetic prosthetic components, in order to achieve a satisfactory aesthetic result.

Keywords: Implant prosthesis, Osseointegrated implant, Aesthetic rehabilitation.

Introduction

Osseointegrated dental implants are generally used for prosthetic rehabilitation of patients with only one missing tooth, or those who are missing several or all of their teeth. The term “osseointegration” was originally used to designate “direct contact between vital bone and the surface of an implant subjected to functional load,” or that may not yet have been subjected to functional load but is capable of supporting the loads to which it will be exposed. Since that time, new concepts have emerged, but they all refer to the direct joining of the vital bone and the implant surface, at the optical microscopy level (Pereira, 2012).

According to Figueiredo (2011), when such rehabilitation is performed in the anterior area of the upper jaw, the major aesthetic requirement involved in this type of procedure should be taken into account. The use of osseointegrated implants has greatly contributed to a better resolution of such cases, because they allow the missing element to be replaced by a tailored crown that is similar to a natural tooth.

Accordingly, thoroughly detailed planning is required, starting from the surgical phase, with regard to the type of implant that will be used and whether bone graft or gum graft will be necessary, in a procedure subsequent to the placement of the implants, in order to obtain healthy gingival tissue and formation of papillae, as well as to ensure, aesthetically, that the implant looks as natural as possible. The purpose of this study was to exemplify and discuss – through a clinical case report – the planning and execution of a rehabilitation treatment with a dental implant and an implant-supported prosthesis in an aesthetic area of the patient’s maxilla, namely, the upper left central incisor, tooth #21 (FDI notation).

Literature review

Osseointegrated implants have been used in humans since the 1960s for rehabilitation of patients missing all of their lower teeth.

They were later used for partially edentulous patients and, more recently, in the early 1990s, for cases of individual tooth loss, with the major advantage of preserving the neighboring teeth and the ease of cleaning (Branemark, et al., 1985).

Xenogeneic grafts (xenografts) are those from individuals of different species. Bovine bone is widely used, and has exhibited satisfactory results in the correction of alveolar defects (Klinge et al., 1992; Hislop et al., 1993; Jensen et al., 1996; Schou et al., 2003) as well as in peri-implant repairs. (Dies et al., 1996; Berghlund e Lindhe, 1997).

One important consideration involves the growth potential of the maxilla, reason whereby it has been suggested that implants should only be placed after the age of 15 years in females and 18 in males, according to Oesterle L.J. (1993).

When implants are used for rehabilitation in an aesthetic region, the 28 peri-implant tissues can be worked at four different times: before implant placement; simultaneously with implant placement; during the healing phase, in the second surgical stage; and during the maintenance phase. There is no single indication for working peri-implant tissue, as patients show up for treatment at widely varying stages. Each case must be evaluated individually, designating an appropriate treatment plan. The earlier peri-implant tissues are treated, the greater the chances for successful results. For the authors, handling soft tissue is becoming the key to guiding the aesthetics of implant-supported restorations. Flaws such as insufficient bone structures, discrepancy between the natural root shape, implant design, or improper implant position/angulation may impair the support of peri-implant soft tissue, according to Hurzeler and Weng (1996).

Jovanovic (1997) identified that for good aesthetic results and an optimal emergence profile of implant restorations, it is important to maintain and increase the vertical and horizontal bone dimensions following extractions. Reconstructive surgery can be divided into two basic areas, to simplify its understanding: anterior (segments where the implant-supported restorations are aesthetically visible); and posterior (segments where the aesthetic consequence is hardly perceived in the result). Factors such as high visibility of the anterior region of the upper jaw and horizontal or vertical bone deficiency are the most common challenges. Aesthetic implant restorations depend on a suitable bone base, as well as soft tissue in the appropriate quantity and quality. For SURIN, S. (2002), the following prerequisites have established good aesthetics in dental implants: a) adequate bone volume (horizontal and vertical contour); those developed by Prof. P; optimal implant position (mesiodistal, apical-coronal, angulation); healthy and stable peri-implant soft tissue; aesthetic contours of the soft tissue; e) natural subgingival emergence profile.

For Garg; Finley; Dorado (1997) planning the placement of single implants is essential, and should include everything from the placement of certain tooth shapes, the emergence profile and screw location, to the dimensions of the interproximal papilla. In addition to preoperative radiographs, proper clinical examination and surgical guide are necessary to achieve harmony of the interproximal papilla and gum tissue. The apical and occlusal position of the implants should also be taken into account; the implant should be placed 3.0 mm below an imaginary line drawn between the gingival margin of the adjacent natural teeth. Collapse of soft tissue may occur with increased depth, creating difficulties with setting, molding the coping, and the overall result of the restoration. Placement of the final prosthetic component during the surgical procedure in the second stage may result in exposure of the titanium metal line, due to a recession or change in the soft tissue dimensions. A healing abutment or temporary prosthetic healing component, of the same width as the root, should be placed to secure the second surgical stage, leading the soft tissue to heal. This creates an ideal space for the prosthetic restoration, which would be similar to the outline of the lost tooth, bestowing a more natural appearance through the marginal gums, according to SURIN, S. (2002).

Figuroa et al. (2014) consider IPS E.MAX as a versatile system, and currently it has become an excellent alternative as a rehabilitation system, both aesthetically and functionally, because it is able to achieve an excellent balance between the patient's smile and the aesthetics of dental rehabilitations.

The IPS E.MAX Press System has been widely used in aesthetic prostheses. It basically consists of a glass-ceramic substructure based on 60% lithium disilicate ($\text{Li}_2\text{Si}_2\text{O}_5$). IPS E.MAX Press ceramic has two crystalline phases and a glassy phase in its composition. The primary crystalline phase is formed by elongated lithium disilicate crystals, and the secondary phase is composed of lithium orthophosphate. The vitreous matrix involves both crystalline phases (CARVALHO et al., 2012).

Case Report

Patient R.G.K.C., male, 18 years old, came to the institution complaining of aesthetic impairment in the region of the upper left central incisor, tooth #21 (in FDI notation), resulting from the avulsion thereof as a result of a cycling accident that had occurred more than seven years prior. The patient was completing orthodontic treatment. (Figure 1)

After performing a clinical examination, CT imaging (Figure 2) and rehabilitation planning, treatment was initiated with the surgical part (Figures 3, 4, 5), whereby we opted to install a Morse Cone implant (Systex®, attract 3.5 x 15 mm platform switching), with draining of the incisive foramen, bone grafting with bovine mineral bone structure (LUMINA-BONE, Criteria®, Medium Granules: 425 to 600 μ – 0.6cm³), and use of a bovine collagenous membrane, LUMINA-COAT, Criteria®, dimension 1x20x30mm), due to buccal plate fenestration and for buccal volume gain.

We used the modified Summers technique, leaving 3.0 mm infra-bone clearance in order to provide the correct size of prosthetic crown. A 3.3x1.5 mm healing abutment was immediately installed over the implant, with 60N implant torque, and stitched with nylon suture. The final appearance after the surgery is shown in Figure 6. During this period, the patient used a mobile device with tooth #21 affixed to it.

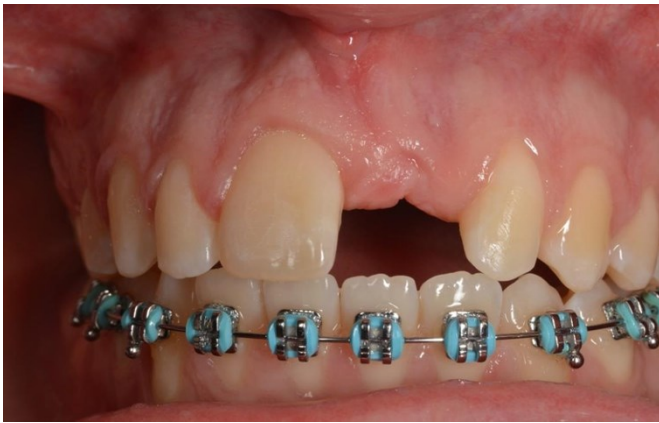

Figure 1 - Aesthetic defect of patient's smile due to the absence of tooth #21 (FDI notation)

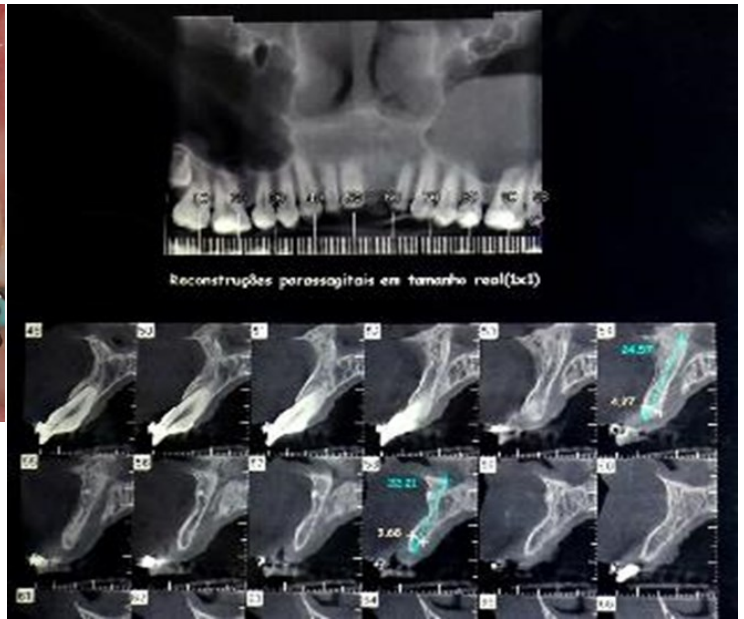


Figure 2 - CT scan

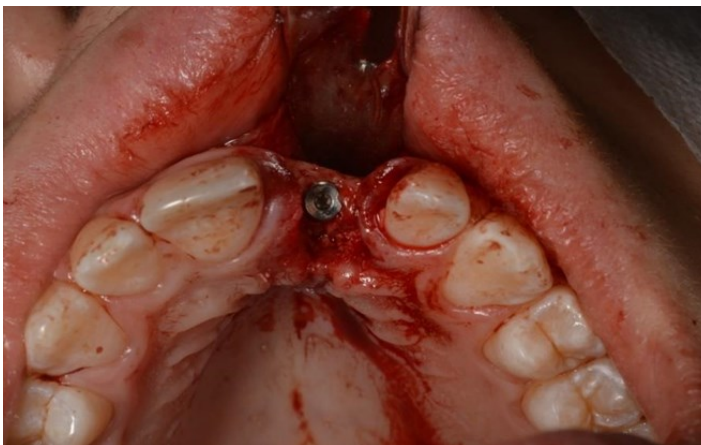


Figure 3 - Surgical phase: Installation of the Morse Cone Implant

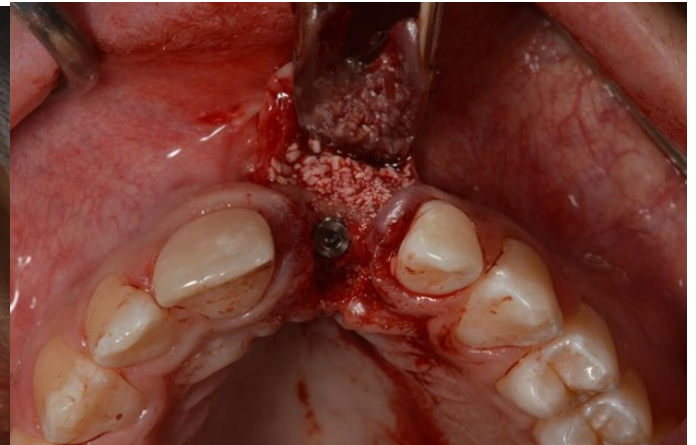


Figure 4 - Surgical phase: Bone grafting

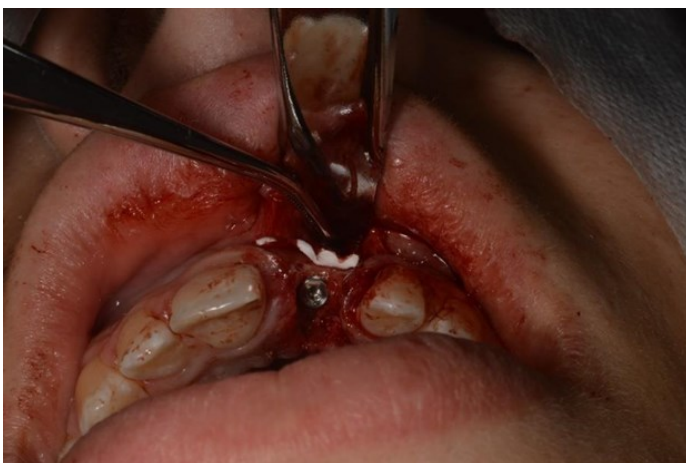

Figure 5 - Surgical phase: Insertion of the collagenous membrane

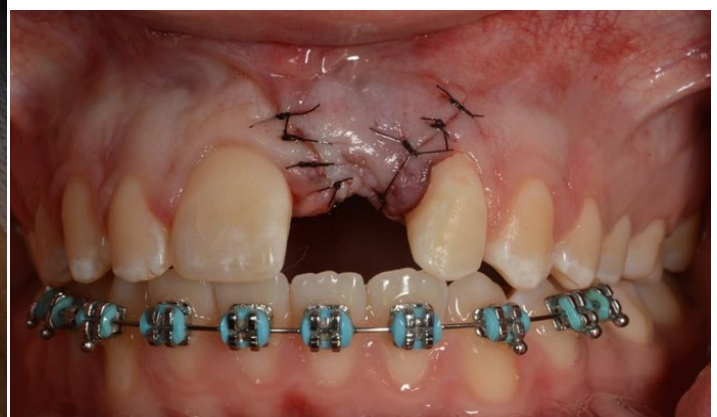

Figure 6 - Final appearance after surgery

After a four-month waiting period for osseointegration and healing (Figure 7), surgery was performed in order to reopen the implant and install a universal abutment, height 7.0 x 3.5 - ICM (SYSTEX® Prosthesis System), at the manufacturer-recommended torque (Figure 8), using the Palacci technique to allow the formation of a papilla between the implant and the adjacent teeth. In the same stage, the temporary crown of tooth #21 was manufactured (Figure 9); thus, in the following appointment, conditioning of the peri-implant tissue was initiated by gradually adding acrylic resin under the prosthetic crown, to obtain an aesthetically more favorable appearance of the mucosa. At this time, the patient opted for at-home tooth whitening using 16% carbamide peroxide, for a period of four hours a day, for 21 days (Whiteness FGM®).

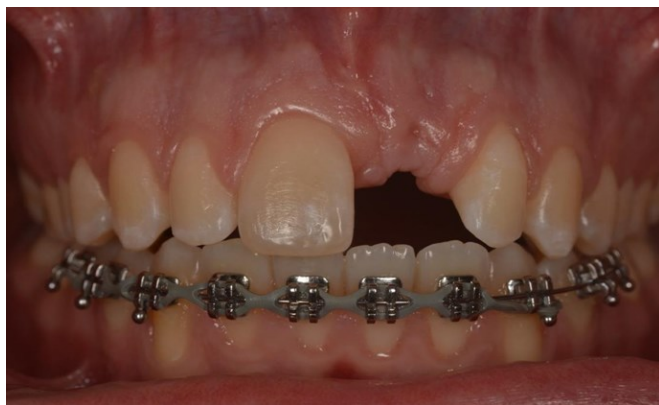

Figure 7 - Scarring appearance after the osseointegration period.

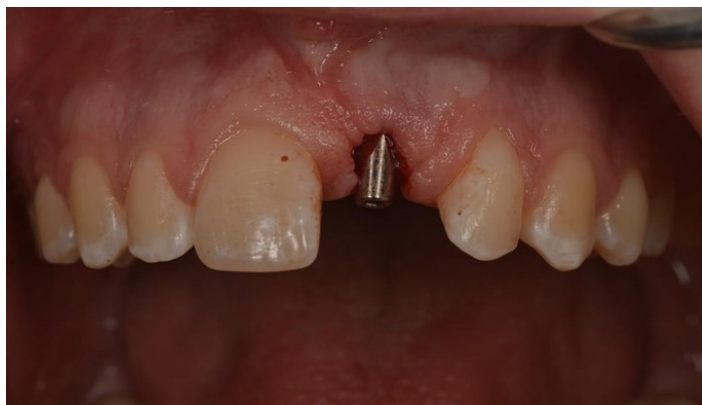

Figure 8 - Photo of the surgery for reopening and installation of the prosthetic component.

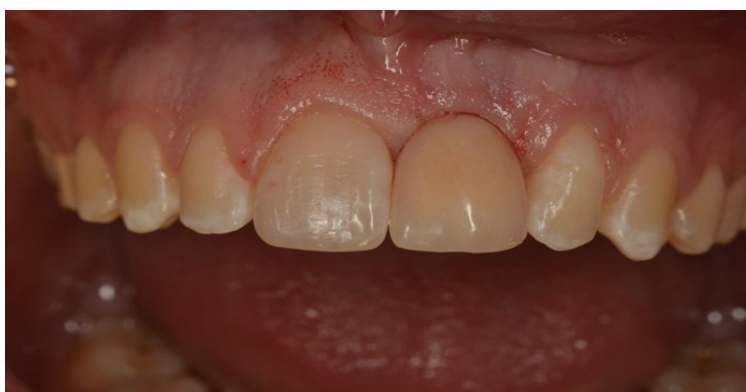

Figure 9 - Installation of provisional crown on implant.

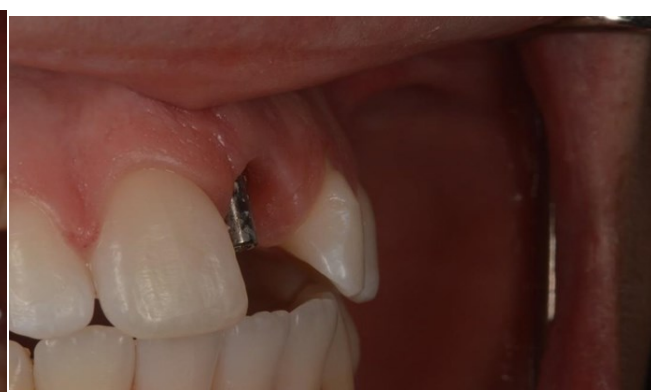

Figure 10 - Appearance of the peri-implant mucosa after gum conditioning.

Having achieved the desired result with the gum conditioning procedures, (Figure 10), after four months the universal transfer abutment (Figure 11) was installed. We used the modified technique for customizing the transfer abutment by applying TOP DAM - FGM® (Cecato R.C., 2017) around the peri-implant area (Figure 12). Then, the transfer molding of the prosthetic abutment was performed, with a closed plastic tray; the material of choice was addition silicone (Express XT - 3M ESPE®) (Figure 13).

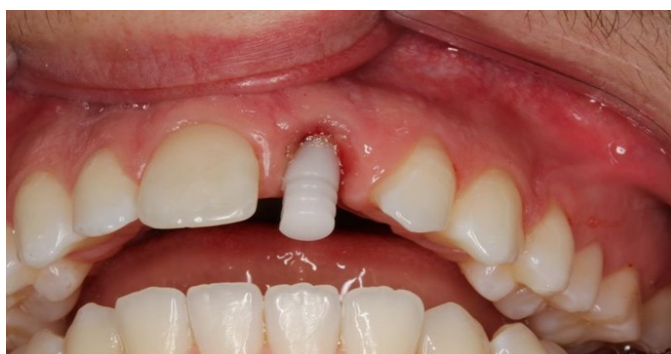

Figure 11 - Installation of the transfer abutment.

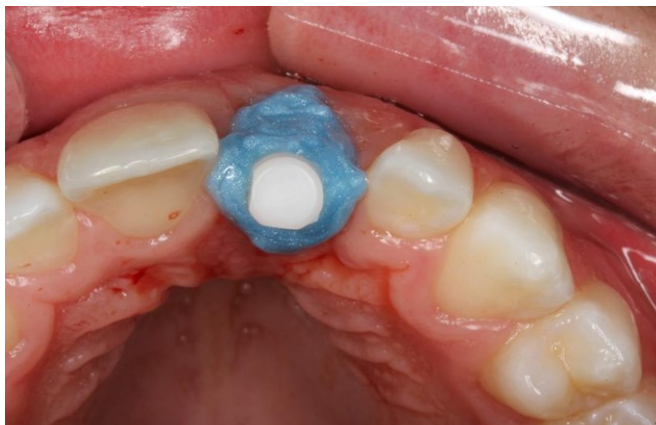


Figure 12 - Installation of the transfer abutment and technique for copying the marginal termination.

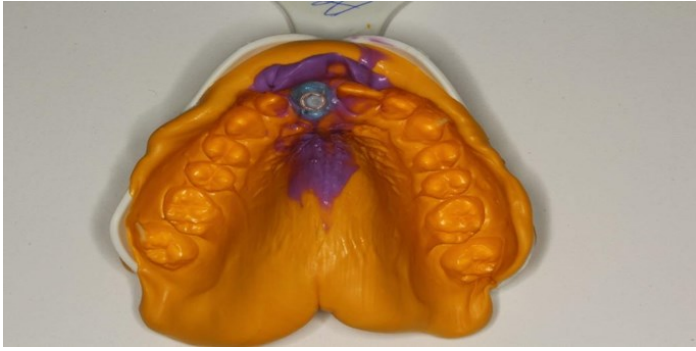

Figure 13 - Photo of the mold after transferring tooth #21.

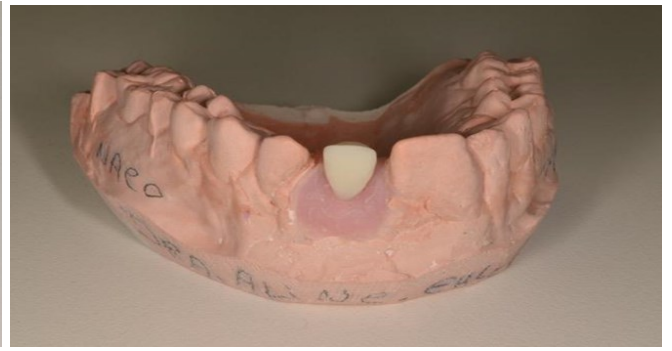


Figure 14 - Photo of the coping made by the laboratory.

In the next session, the ceramic coping proof was installed on the abutment (Figures 14 & 15). This was followed by a bite record using Optosil – Heraeus Kulzer® condensation silicone (Figure 16), in addition to color selection (A1, Vita system), to guide porcelain application. (Figure 17).

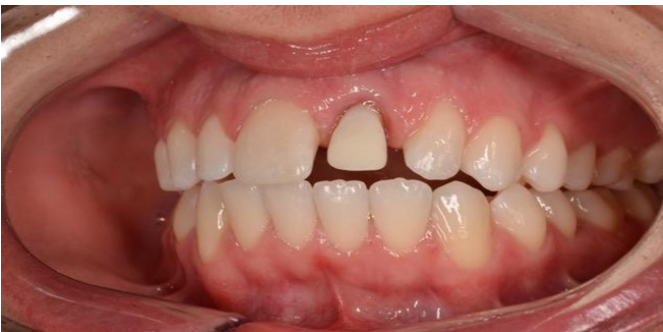

Figure 15 - Photo of the E-MAX® ceramic coping proof.

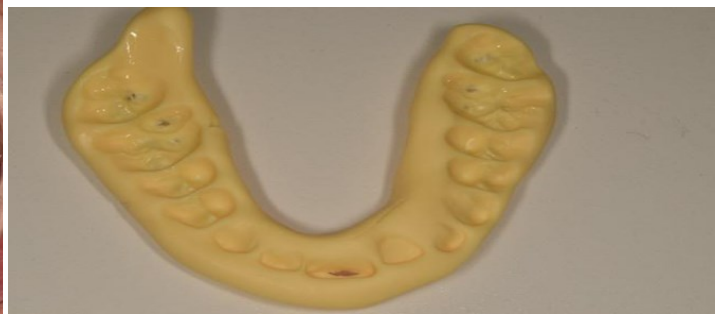

Figure 16 - Bite record with condensing silicone.

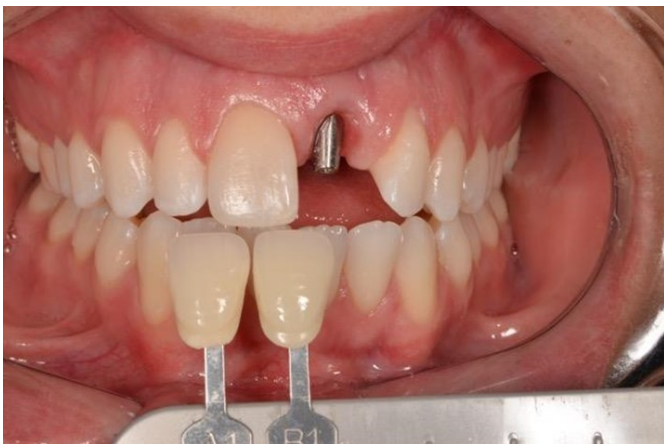

Figure 17 - Color selection according to the Vita® system.

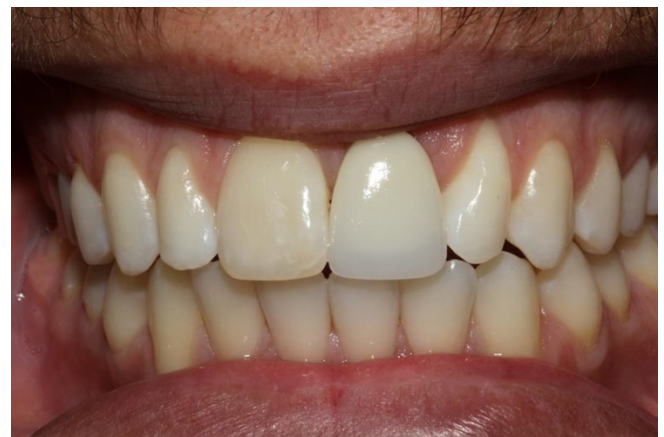

Figure 18 - Appearance of the crown immediately after cementing.

The prosthetic part was cemented with dual relynx U200-3M resin cement, according to the manufacturer's instructions, and the occlusal contacts were checked.

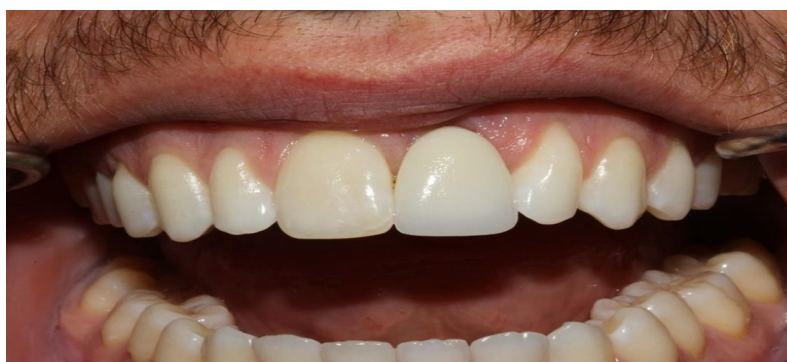

Figure 19 - Appearance of the crown immediately after cementing.

Discussion

According to AL-SABBAGH (2016), in order to achieve a successful aesthetic result and appropriate patient satisfaction, the installation of implants in the aesthetic zone requires an understanding of anatomical, biological, surgical, and prosthetic principles. Installing a prosthesis that is harmonious with and indistinguishable from adjacent natural teeth in the aesthetic zone is often challenging and requires skill. Placing dental implants within the aesthetic zone is a technique-sensitive procedure with little room for error. Guidelines are offered for optimal placement of the implant as well as for a wide range of therapeutic modalities that can be implemented to approach different clinical situations that involve replacement of missing teeth within the aesthetic zone.

Prosthetic rehabilitation in the upper anterior central incisor region can be done using a removable partial prosthesis; provisionally with a fixed prosthesis; more invasive; involving the preparation of adjacent teeth, or with implant-supported prostheses, which involves favorable systemic condition of the patient and a surgical procedure but is the most popular in terms of rehabilitative treatment of only one missing tooth.

Gum conditioning was essential for the aesthetic success of the rehabilitation, especially in the maxillary anterior region, known as the “aesthetic zone”, with management of peri-implant soft tissue, involving everything from correct flap positioning, surgical techniques with well-planned and properly executed incisions and appropriate suturing techniques, to the use of gum conditioning maneuvers during the prosthetic stage, in order to achieve successful aesthetic, functional and biological rehabilitation of the site between the prosthesis and the peri-implant mucosa (OLIVEIRA, 2002).

In this case, for the conditioning of the gum tissue, the gradual pressure technique was used, whereby small portions of chemically activated acrylic resin were added to a provisional prosthesis, in such a way that there is suitable clearance of the peri-implant mucosa, in order to remodel it, according to the dental practitioner’s interest, always respecting biological principles, with convex pontics, appropriate emergence profiles, and interdental space for the papillae, according to the literature (Neale, 1994). Tripodakis, 1990.

The intermediate abutment of choice depends on each case, and it is up to the practitioner to choose the most suitable one. In this case, the universal metal abutment was used, of the same brand as the implant (Systex®), which is relatively low-cost and very practical; it also allows for correcting the slope of the implant, if necessary, using factory-made angled intermediate abutments or even abutments that are customizable by the laboratory or dental surgeon.

The high demand for aesthetic restorations, particularly in the anterior region, has made ceramic material the number-one choice among dentists. Ceramic prostheses offer such aesthetic value that they can be used in implant-supported restorations with no loss of quality in the final work (Razzoog et al., 1999).

The dental ceramic material most often chosen was E-MAX., also known as dental porcelain. This material is known for having an appearance very similar to natural teeth, due to its highly suitable optical properties and chemical durability. These and other qualities – such as excellent aesthetics and hardness – have led to the rapid development of this material in the scientific context regarding its properties, primarily aimed at attempting to satisfy modern society’s increasing aesthetic demands (GOMES et al., 2008).

In this clinical case report, using the technique of bone grafting and installation of a dental implant in the same session and waiting a suitable period of time for osseointegration, while maintaining a provisional prosthesis without touching the operated area, we succeeded in preserving peri-implant tissue and recovering bone thickness in the upper left central incisor region, tooth #21 (FDI notation).

Conclusion

We can conclude that the rehabilitation of an anterior maxillary edentulous area is rather comprehensive, as it is often necessary to provide a complex rehabilitation treatment, such as bone grafting, connective tissue graft, adaptation and conditioning of the gum contour and papillae, and the choice of the most suitable prosthetic component, type of porcelain, color, and shape. It is truly a very delicate effort, especially when dealing with just one anterior central incisor, and requires thorough knowledge and skilled technique from the practitioner.

Conflict of Interest

The authors declare that there is no conflict of interest.

Acknowledgments

Special thanks to the entire team of the Periimplanteam group for their support in the development of this paper.

References

1. AL-SABBAGH, Mohanad, DDS, MS, Implants in the Esthetic Zone, *Dent Clin N Am* 50 ,391–407. (2006).
2. ASKARY AS. Multifaceted aspects of implants aesthetics: the anterior maxilla. *Implant Dent.* 2001;10(3):182-91.
3. BERGHLUND T, Lindhe J. Healing around implants placed in bone defects treated with Bio-Oss. An experimental study in the dog. *Clin Oral Implants Res*, 1997;8:117-124 BERNARD JP, Schatz JP, Christou P, et al.
4. Long-term vertical changes of the anterior maxillary teeth adjacent to single implants in young and mature adults. A retrospective study. *J Clin Periodontol* 2004;31(11):1024–8.
5. BRANEMARK PI, Adell R, Breine U, Hansonn BO, Lindstron J, Ohlsson A. Intra- osseous anchorage of dental prostheses. Experimental studies. *Scand J Plast Reconstr Surg* 1969;3(2):81-100.
6. CARVALHO, R. L. de A. et al. Indicações, adaptação marginal e longevidade clínica de sistemas cerâmicos livres de metal: uma revisão da literatura. *Int. J. Dent., Recife*, v. 11, n. 1, p. 55-65, jan./mar. 2012.
7. CECATO, R.C. Implante imediato com carga imediata utilizando sistema arcsys. Net. Florianópolis, março.2017. Seção Artigos. Available at: <<http://blog.suryadental.com.br>>. Access on April 1, 2017.
8. DIES F, Etienne D, Abboud NB, Ouhayoun JP. Bone regeneration in extraction sockets after immediate placement of an e-PTFE membrane with or without a biomaterial. Report on 12 consecutive cases. *Clin Oral Implants Res*, 1996;7:277-285.
9. FIGUEIREDO, C. M., et al. O uso de implantes, enxerto ósseo e condicionamento do tecido gengival perimplantar na reabilitação estética de área anterior de maxila. *Odontol. Clín.-Cient., Recife*, 10 (3) 285-291, jul./set., 2011 .
10. FIGUEROA, Rolando Ignacio et al. Rehabilitación de los Dientes Anteriores con el Sistema Cerámico Disilicato de Litio. *Int. J. Odontostomat., Temuco*, v. 8, no. 3, p. 469-474, dic. 2014.
11. GARG, A.K.; FINLEY, J.; DORADO; L.S. Single-Tooth Implant —Supported Restorations in the Anterior Maxilla. *Pract. Periodontics Aesthetic Dent., New York*, v. 9, n. 8, p. 903-910, June.1997.
12. GOMES, E. A. et al. Cerâmicas odontológicas: o estado atual. *Cerâmica, São Paulo*, v. 54, n. 331, p. 319-325, set. 2008.
13. HISLOP WS, Finlay PM, Moos KF. A preliminary study into the uses of anorganic bovine bone in oral and maxillofacial surgery. *Br J Oral Maxillofac Surgery*, 1993;31:149-153.
14. HORZELER, M.B. ; WENG, D. Periimplant Tissue Management: Optimal Timing for na Aeslhetic Result. *Pract. Periodontics Aesthetic Dent., New York*, v. 8, n. 9, p. 857-869, Nov/dec. 1996.
15. ISERI H, Solow B. Continued eruption of maxillary incisors and first molars in girls from 9 to 25 years, studied by the implant method. *Eur J Orthod* 1996;18(3):245–56.
16. JENSEN SS, Aaboe M, Pinholt EM, Hjorting-Hansen E, Melsen F, Ruyter IE. Tissue reaction and material characteristics of four bone substitutes. *Int J Oral Maxillofac Implants*, 1996;11:55-66.
17. JOVANOVIC, S.A. Bone Rehabilitation to Achieve Optimal Aesthetics. *Pract. Periodontics Aesthet. Dent., New York*. v. 9, n. 1, p.41-52, Jan./ Feb.1997.
18. KING GN, King N, Hughes FJ. Effects of two delivery systems for recombinant human bone morphogenetic protein-2 on periodontal regeneration in vivo. *J Periodontal Res*, 1998;33:226-236.
19. MONDELLI, J. Estética e cosmética em clínica integrada restauradora. São Paulo: Ed. Santos, 2003.
20. NEALE D, Chee WWL. Development of implant soft tissue emergence profile: A technique. *J Prosthet Dent.* 1994;71 (4):364-8.
21. OESTERLE LJ, Cronin RJ Jr, Ranly DM. Maxillary implants and the growing patient. *Int J Oral Maxillofac Implants* 1993;8(4):377–87.
22. OLIVEIRA JA. Condicionamento gengival: estética em tecidos moles. *Fac Odontol Bauru.* 2002;10(2):99-104
23. PALACCI P, Nowzari H. Soft tissue enhancement around dental implants. *Periodontol* 2000. 2008;47:113-32.
24. PEREIRA, Jefferson Ricardo. Prótese sobre implante. Artes Médicas, São Paulo-SP, 2012. RAZZOOG, M. E. et al.
25. All Ceram crowns for single replacement implant abutments, *J. Prosthet. Dent., St. Louis*, v.78, n.3, p.486-488, Nov. 1999.
26. SCHOU S, Holmstrup P, Jørgensen T, Skovgaard LT, Stoltze K, Hjorting-Hansen E, Wenzel A. Anorganic porous bovine-derived bone mineral (Bio-Oss) and ePTFE membrane in the treatment of peri-implantitis in cynomolgus monkeys. *Clin Oral Impl Res*, 2003;14:535-547.
27. SUMMERS, R.B. The osteotome Teclmique: part 2. The fidge expansion osteotomy (REO) procedure; *Compend. Conto Educ. Dent.* 1994.
28. SUZIN, SORIANE. Otimização da estética em próteses implanto-suportadas. Trabalho de conclusão de curso (Pós-Graduação em Prótese Dentária) – Universidade Federal de Santa Catarina, Florianópolis, 2002.

29. TRIPODAKIS AP, Constandtinides A. Tissue response under hyper pressure from convex pontics. Int J Periodontics Restorative Dent. 1990;10(5):408-14

Citation: Ehlert A, Lacerda CCC, da Silva Baracho NC, Freitas BS, Poblete FAO, Martin SCR, de Lima Sousa LL, Margute TG. "Aesthetic Rehabilitation with a Dental Implant in an Upper Central Incisor". SVOA Dentistry 3:1 (2022) Pages 366-373.

Copyright: © 2022 All rights reserved by Margute TG., et al. This is an open access article distributed under the Creative Commons Attribution License, which permits unrestricted use, distribution, and reproduction in any medium, provided the original work is properly cited.